

The Use of SMI in Surveillance of Endovascular Aneurysm Repair

Prof. Neil Pugh

Consultant Clinical Scientist

Cardiff and Vale University Health Board, United Kingdom

Introduction

Endovascular aneurysm repair (EVAR) has rapidly become the treatment of choice in the repair of abdominal aortic aneurysms (AAA). Whilst EVAR using commercially available devices has been associated with a low rate of aneurysm-related death, late aneurysm rupture is a potential risk of all devices. Therefore, continued surveillance after EVAR to detect aneurysm growth due to endoleak, device migration, or structural failure is recommended [1]. There has been much discussion regarding the optimal imaging strategy for EVAR surveillance. Initial studies recommended computed tomography arteriography (CTA) at one, six, and 12 months after initial repair and yearly thereafter [2]. However, the frequent use of CTA has raised concerns about the cumulative effects of radiation from repeat exposure and the lifetime risk of cancer, in addition to the added cost of these studies.

This led some to question whether colour duplex ultrasound (CDUS) could replace CTA. Although ultrasound avoids radiation exposure and the nephrotoxicity of iodinated contrast agents, concerns were raised regarding the sensitivity of ultrasound in identifying endoleaks [3, 4]. However, more recent studies have suggested that the lower sensitivity of CDUS is offset by a high degree of correlation between CDUS and CTA in the detection of clinically significant endoleaks [5]. If neither an endoleak nor residual aneurysm sac enlargement is documented on the first annual CTA, most centres will use a combination of CTA, CDUS, and plain abdominal radiography at six-month or yearly intervals to follow up the EVAR [6]. Thus, the Society for Vascular Surgery recommends annual surveillance with either CTA or CDUS if the original post-operative CT scan does not demonstrate any of the above concerns [7].

Nevertheless, convention has dictated that if an endoleak is detected, particularly a type II endoleak, it should be followed up by CTA due to the reduced sensitivity of CDUS. Consequently, many centres have reported the use of contrast-enhanced ultrasonography (CEUS) as an alternative to CTA due to the improved spatial resolution of CEUS over conventional CDUS. The accuracy of CEUS in detecting endoleaks has been shown to be markedly better than CDUS and similar to CTA and MRA [8]. However, CEUS has limitations and the potential for adverse effects and contraindications. It also takes ultrasound from the realms of a non- or minimally invasive procedure to a more invasive, costly and time-consuming investigation. Recently, Toshiba Medical Corporation has developed a novel microvascular flow imaging technique called SMI (Superb Microvascular Imaging) which has been implemented on its new

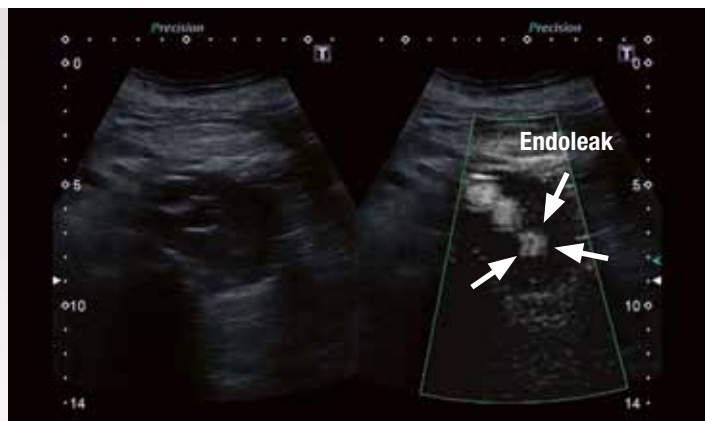


Fig. 1a: Small endoleak demonstrated with mSMI.

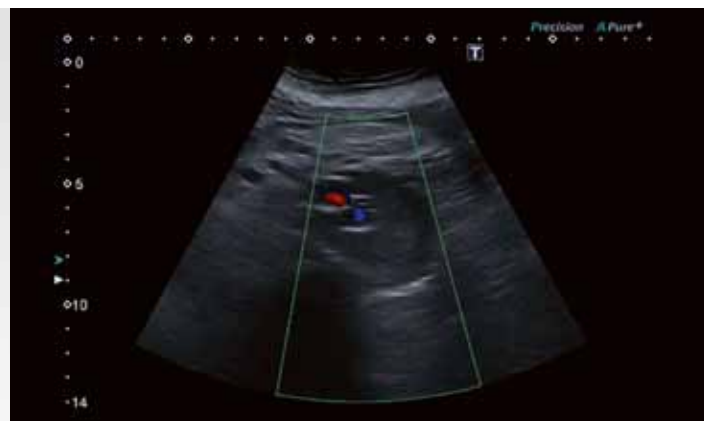

Fig. 1b: Conventional CDUS image fails to show the endoleak seen with mSMI.

Aplio 500 & 400 ultrasound scanners. SMI is a Doppler imaging technique that is able to visualize smaller vessels with lower velocities than conventional CDUS. In addition, SMI retains high frame rates and has little motion artefact, making the imaging of the microvasculature a possibility without the use of contrast. SMI displays flow either in a colour (cSMI) or a monochrome map (mSMI) with the latter having a similar appearance to CEUS [9].

SMI has already been used to image neoplasms, in inflammatory diseases and in the diagnosis of ischaemia [9, 10]. At the University Hospital of Wales in Cardiff, we looked to see if SMI could be used for surveillance of EVARs and if the sensitivity of endoleak detection was equal to or better than conventional CDUS. In addition, we compared the rate of endoleak detection in any patient undergoing CTA for EVAR surveillance.

Methods

A retrospective analysis was performed on the data of all patients enrolled on our EVAR surveillance programme from the 1st of July 2014 to the

30th June 2015 for audit purposes. This period was chosen to include all the studies performed after the installation of SMI on our Aplio 500. All patients were scanned by one of three Medical Physicists trained in vascular ultrasound. A standard scanning procedure was adopted in all cases. The abdominal aorta above the stent graft, the stent graft itself, the residual aneurysm sac and the iliac vessels were scanned in longitudinal and transverse planes using B-mode imaging. The maximum diameter of the residual aneurysm sac was measured in the transverse plane, with both the anterior-posterior and the transverse diameters recorded. The residual aneurysm sac and patency of the limbs of the stent graft were assessed with both CDUS and SMI in both the transverse and longitudinal planes. Particular attention was paid to anechoic areas within the residual aneurysm sacs, looking for any potential endoleaks. A standard protocol for reporting the results of the ultrasound surveillance scans was adopted. The maximum diameter of the residual aneurysm sac and whether the intra-aneurysm content was homogeneous or heterogeneous was

documented from the B-mode image. Any flow within the sac and outside the limbs of the graft was reported as an endoleak and an attempt was made to document the type of endoleak (Type I, II & III) from the CDUS and SMI images.

As not all patients underwent a CTA, a search of the radiology database was undertaken to find those patients in the ultrasound surveillance group who also underwent a CTA.

Results

In the 12-month period from the 1st of July 2014 to the 30th June 2015, 139 patients underwent EVAR surveillance. Three patients were excluded from the analysis and the surveillance programme due to inadequate ultrasound examinations (unable to adequately image the EVAR). Of the 136 patients enrolled, 27 patients underwent CTA within one month of the ultrasound examination. A total of 18/136 patients were found to have an endoleak on ultrasound (CDUS & SMI), giving a pick-up rate of 13% in our cohort of patients. 18/27 patients and 17/27 patients showed no

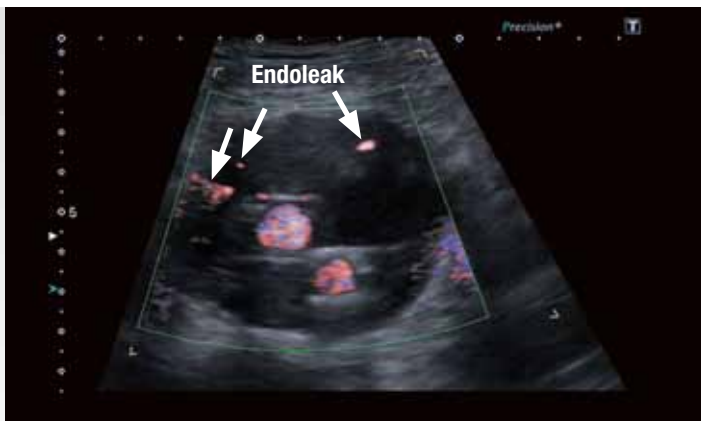


Fig. 2a: Image shows an obvious endoleak with cSMI.

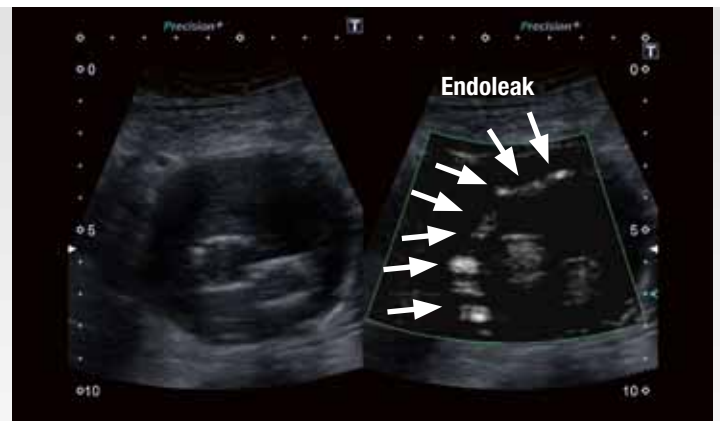


Fig. 2b: This image shows the same endoleak with mSMI. The mSMI image demonstrates the endoleak is more extensive than that seen with cSMI and is more clearly depicted.

endoleak on ultrasound and CTA respectively. Ultrasound failed to demonstrate one endoleak demonstrated with CTA (10% failure rate of ultrasound compared with CTA). In further analysis of the 18/136 patients demonstrating endoleaks on ultrasound, only 10 patients displayed the endoleak on CDUS alone (7% of patients). CDUS failed to demonstrate 8 endoleaks demonstrated with SMI. Both cSMI and mSMI displayed endoleaks not seen on conventional CDUS (Fig. 1), but mSMI displayed the endoleaks with greater clarity than cSMI (Fig. 2). Of the 18 patients displaying an endoleak on SMI, 12 went on to have a CT scan. Out of these 12 patients, 8 patients demonstrated an endoleak on CT. Therefore, in this group of 12 patients, SMI showed a positive endoleak in 4 more patients than were seen on CTA (33% failure rate of CTA compared with SMI). In addition, 2 of the 4 patients with endoleak demonstrated on SMI and not on CT had an expanding sac size.

Discussion

It is generally accepted that CDUS and abdominal x-ray is a safe and effective method of performing EVAR surveillance [6]. However, due to the lack of sensitivity of CDUS in detecting endoleaks compared with CTA, some authors have advocated the use of CEUS in EVAR surveillance [8, 11]. CEUS has been shown to have similar sensitivities to CTA, however, interestingly CEUS has been shown to demonstrate endoleaks not visible on CTA [12]. In a recent study of Perini et al [13], CEUS detected 21 type II endoleaks that were not shown by CTA and CTA showed 17 type II endoleaks that were not shown by CEUS. The two modalities detected the same type I and type III endoleaks and no type IV endoleaks were detected in that study. Our study using SMI has found a similar result to CEUS. We detected more endoleaks with SMI than with CDUS (18 cf. 10). We also found a discrepancy between the numbers of endoleaks demonstrated on SMI compared with CTA. CTA found one endoleak not demonstrated on SMI, however SMI found 4 more endoleaks than CTA, 2 with increasing sac size on ultrasound and CTA. Although our numbers are small and there is no comparison of SMI with CEUS, our results suggest SMI may well be comparable to CEUS in the detection of EVAR endoleaks and outperform CTA in some circumstances.

Conclusion

In conclusion, SMI is an effective tool for the detection of endoleaks in an EVAR surveillance programme. In this limited study, SMI outperforms CDUS in the detection of endoleaks. It appears at least as sensitive as CTA in the detection of endoleaks and has several advantages over the use of CEUS as discussed. Consequently, I believe SMI is a safe tool for use in EVAR surveillance and further studies are warranted to test the sensitivity of SMI compared with CEUS.

References

- Pineda DM, Dougherty MJ, Calligaro KD, Troutman DA
Duplex Ultrasonography and its Use in Surveillance Post-EVAR
J Vasc Med Surg 2015; 3:1
- Sharma P and Kyriakides C
Surveillance of patients post-endovascular aneurysm repair
Postgrad Med J. 2007 Dec; 83(986): 750–753
- Sun Z
Diagnostic value of color duplex ultrasonography in the follow-up of endovascular repair of abdominal aortic aneurysm.
J Vasc Interv Radiol 2006;17:759-64.
- Ashoke R, Brown LC, Rodway A, Choke E, Thompson MM, Greenhalgh RM, Powell JT
Color duplex ultrasonography is insensitive for the detection of endoleak after aortic endografting: a systematic review.
J Endovasc Ther 2005;12:297-305. 493.
- Manning BJ, O'Neill SM, Haider SN, Colgan MP, Madhavan P, Moore DJ
Duplex ultrasound in aneurysm surveillance following endovascular aneurysm repair: A comparison with computed tomography aortography.
J Vasc Surg 2009;49:60-5.
- Harrison GJ, Oshin OA, Vallabhaneni SR, Brennan JA, Fisher RK, McWilliams RG
Surveillance after EVAR Based on Duplex Ultrasound and Abdominal Radiography
Eur J Vasc Endovasc Surg (2011) 42, 187e192
- Chaikof EL, Brewster DC, Dalman RL, Makaroun MS, Illig KA, et al. (2009)
The care of patients with an abdominal aortic aneurysm: the Society for Vascular Surgery practice guidelines.
J Vasc Surg 50: S2-49.
- Cantisani V, Ricci P, Grazhdani H, Napoli A, Fanelli F, Catalano C, Galati G, D'Andrea V, Biancari F, Passariello R
Prospective comparative analysis of colour-Doppler ultrasound, contrast-enhanced ultrasound, computed tomography and magnetic resonance in detecting endoleak after endovascular abdominal aortic aneurysm repair.
Eur J Vasc Endovasc Surg (2011), 41, 186-192
- Hata, J
Seeing the unseen. New techniques in vascular imaging. Superb Micro-Vascular Imaging. Toshiba Medical Review, 2014.
- Machando, P and Forsberg F
Initial experiences with a novel microvascular flow imaging technique.
Toshiba medical review, 2014
- Millen A, Canavati R, Harrison G, McWilliams RG, Wallace S, Vallabhaneni SV, Fisher RK.
Defining a role for contrast-enhanced ultrasound in endovascular aneurysm repair surveillance.
J Vasc Surg 2013;58:18-23
- Cantisani V and Ricci P
Evaluation of the clinical impact of CEUS in the treatment of abdominal aneurysms.
Toshiba medical review, 2011
- Perini P, Sediri I, Midulla M, Delsart P, Mouton S, Gautier C, Pruvo J.-P, Haulon S
Single-centre Prospective Comparison Between Contrast-Enhanced Ultrasound and Computed Tomography Angiography after EVAR.
Eur J Vasc Endovasc Surg (2011), 42, 797-802

TOSHIBA MEDICAL SYSTEMS CORPORATION

©Toshiba Medical Systems Corporation 2015 all rights reserved.

Design and specifications subject to change without notice.

09/2015 MWPUL0031EUC

Printed in Europe

www.toshiba-medical.eu

ULTRASOUND CT MRI X-RAY SERVICES